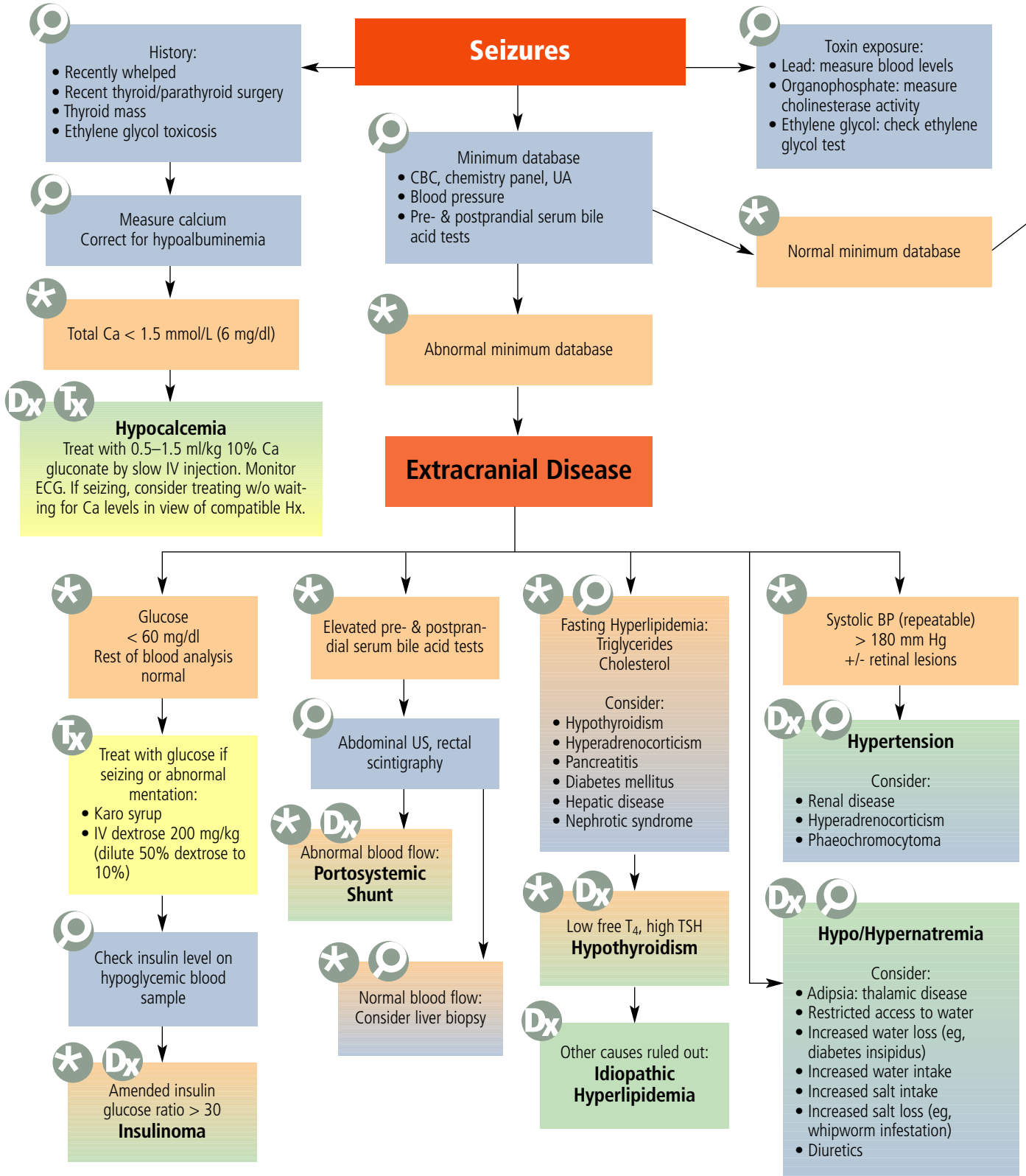


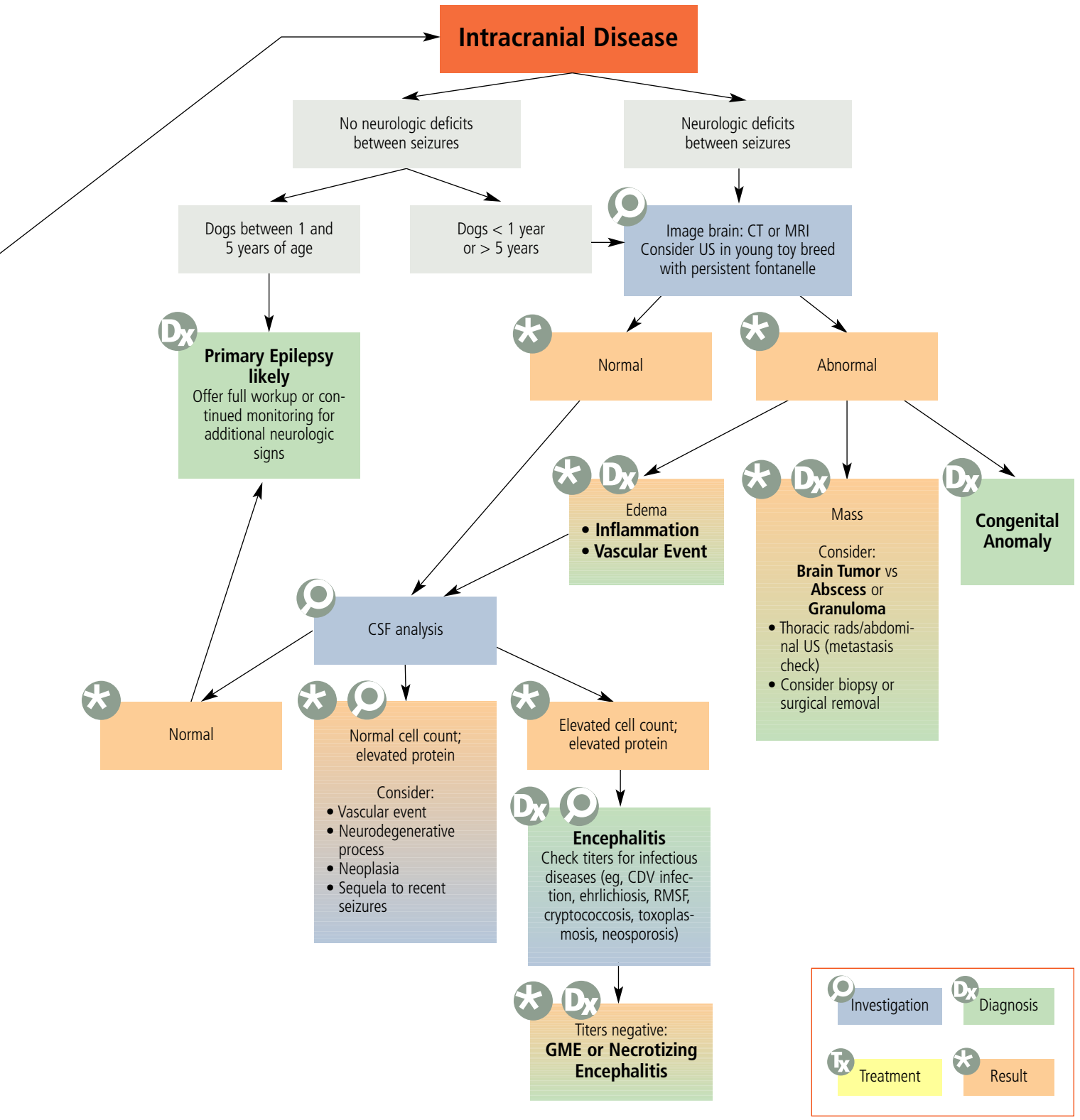
# diagnostic tree

## Intracranial vs Extracranial Seizures

Natasha Olby, VetMB, PhD, Diplomate ACVIM (Neurology), North Carolina State University

Intracranial vs Extracranial Seizures





BP = blood pressure; Ca = calcium; CBC = complete blood count; CDV = canine distemper virus; CSF = cerebrospinal fluid; CT = computed tomography; ECG = electrocardiogram; GME = granulomatous meningoencephalitis; Hx = history; MRI = magnetic resonance imaging; rads = radiographs; RMSF = Rocky Mountain spotted fever; T<sub>4</sub> = thyroxine; TSH = thyroid-stimulating hormone; UA = urinalysis; US = ultrasonography